

Immediate Loading of the Maxilla with Prefabricated Interim Prosthesis Using Interactive Planning Software, and CAD/CAM Rehabilitation with Definitive Zirconia Prosthesis: 2-Year Clinical Follow-up

PANOS PAPASPYRIDAKOS, DDS, MS*
KUNAL LAL, DDS, MS†

ABSTRACT

Immediate loading in implant dentistry has provided several advantages for both patients and clinicians. Recent advances in computer-aided design/computer-aided manufacturing (CAD/CAM) technology, medical imaging and rapid prototyping have added to the armamentarium of implant dentistry in terms of efficiency, accuracy and predictability. Rapid prototyping and CAD/CAM technology are used to fabricate stereolithographic surgical templates for flapless implant placement. In addition to that, this technology is also used for the fabrication of zirconia frameworks. The zirconia-based implant restorations are gaining popularity in implant prosthodontics combining esthetic properties with strength and biocompatibility. The purpose of this article is to illustrate the steps for implant rehabilitation of the edentulous maxilla with zirconia prosthesis and report the 2-year clinical follow-up of novel technological advances in surgical placement, provisionalization and fabrication of a definitive restoration.

CLINICAL SIGNIFICANCE

A comprehensive approach to full mouth implant rehabilitation using cutting edge technology is illustrated in a simplified manner.

(*J Esthet Restor Dent* 22:223–234, 2010)

INTRODUCTION

After the longitudinal effectiveness of the two-stage submerged approach, the predictability and efficiency of immediate loading of implants placed in the edentulous mandible has been well documented in the literature.^{1–4}

The benefits of immediate loading have allowed for shortened treatment time and immediate function with fixed prostheses. Prerequisites for immediate loading are primary stability, cross-arch stabilization, and enhanced roughened implant designs.^{1–5} Initial or primary implant stability is defined as

implant stability at completion of surgical placement. Initial implant stability has been used as a predictor for future osseointegration and whether immediate loading protocol should be applied. The primary stability of inserted implants is directly associated with resistance to micromotion during the healing

*Implant fellow, Department of Restorative Dentistry and Biomaterials Sciences, Harvard University, Harvard School of Dental Medicine, Boston, MA, USA

†Assistant professor, Division of Prosthodontics, Columbia University College of Dental Medicine, New York, NY, USA

period. Obtaining primary stability is affected by surgical technique and implant design, which are important especially in soft bone, where implant failures are more likely.⁵ Initially, application of immediate loading in the maxilla was precluded due to the specific characteristics of the maxillary jawbone, such as the softer bone quality, leading to lower insertion torques and poor primary stability.⁵ With the advance of technology, researchers and clinicians, in order to reduce treatment time and increase patient comfort have started implementing immediate loading protocols for the edentulous maxillae in carefully selected cases with caution.^{5,6}

Recent advances in computer-aided design/computer-aided manufacturing (CAD/CAM) technology in combination with computed tomography (CT) medical imaging and rapid prototyping have enabled more accurate and less invasive flapless surgical implant placement.⁷⁻¹⁰ Benefits of flapless implant placement include reduced healing times, fewer changes in crestal bone levels, less bleeding, and minimal postoperative discomfort and swelling.¹¹ There is a growing interest in minimally invasive implant therapy as a standard treatment, providing complete restoration of function. Surgical placement and prosthesis construction can now be performed prior to

the actual surgical procedure.¹²⁻¹⁴ Additive rapid prototyping is used to fabricate stereolithographic surgical templates.¹² CAD/CAM technology and subtractive rapid prototyping are used for design and fabrication of the zirconia frameworks. Similarly, zirconium oxide, also known as zirconia, has gained increasing popularity in contemporary dentistry due to its biocompatibility, high flexural strength, toughness, and esthetic properties.^{15,16} It is currently being used for the fabrication of all ceramic copings and frameworks for both fixed prosthodontics and implant dentistry.^{16,17}

The purpose of this clinical report is to describe the application of these technological advances in comprehensive implant rehabilitation. CAD/CAM technology and additive rapid prototyping were used to fabricate stereolithographic surgical templates for flapless implant placement and prefabricated interim prosthesis to facilitate immediate loading, whereas subtractive rapid prototyping was employed to fabricate the zirconia framework for the definitive full arch prosthesis.

CLINICAL REPORT

A 62-year-old fully edentulous male presented at the Postdoctoral Prosthodontic clinic of Columbia University College of Dental Medicine with a maxillary complete

denture opposing a two implant-supported mandibular overdenture. He was seeking implant treatment due to his inability to tolerate the maxillary complete denture, during speech and function. Most importantly, he stressed the psychologic impact of having a removable maxillary denture.

Careful review of the patient's medical history indicated no remarkable conditions that could affect the prognosis of treatment with implants. Patient classification according to House's classification was philosophical, being responsible in terms of following appointments, indications, and oral health maintenance. Comprehensive diagnostic work up was carried out. Upon radiographic and intraoral examination, the patient was characterized as Class II according to the PDI Complete Edentulism Classification system. It was found that the patient had the adequate quantity and quality of alveolar bone to allow for implant treatment (Figure 1). Time restraints existed due to specific work obligations. After thorough discussion with the patient, a minimally invasive flapless surgical and prosthetic implant protocol (Teeth-In-An-Hour™) was recommended and patient's approval and informed consent was obtained.

The patient's existing dentures were assessed for esthetics,

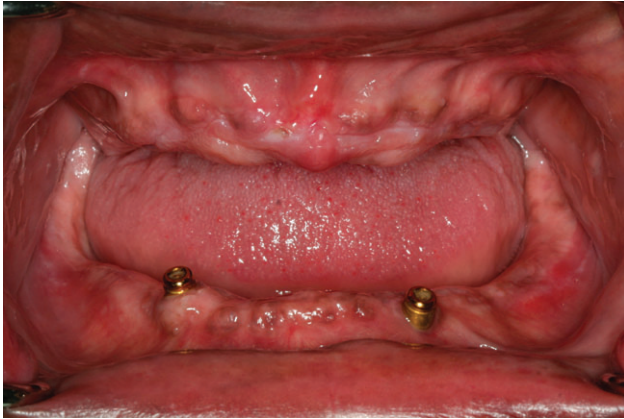

Figure 1. Pre-treatment intraoral condition.

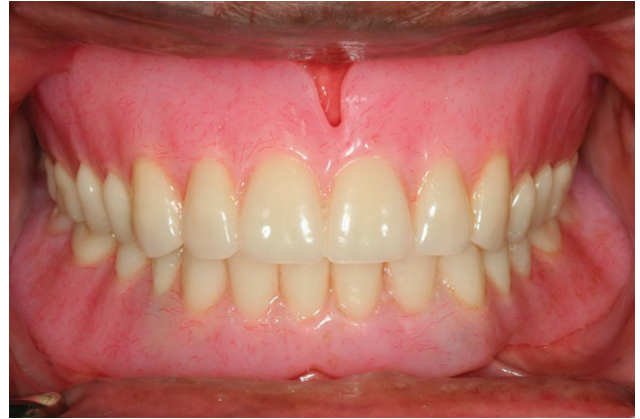

Figure 2. Existing complete dentures.

phonetics, occlusal vertical dimension (OVD) and teeth mold and were found acceptable (Figure 2). The properly designed maxillary removable complete denture was duplicated with clear acrylic resin in order to fabricate the radiographic template. Interocclusal centric relation (CR) records and a facebow registration were taken in order to articulate the maxillary duplicate denture and the mandibular denture cast. Twelve radiopaque markers were made with gutta-percha, and a CT double scan was prescribed.¹²⁻¹⁴ The use of CT with calculations of bone mineral density is an indispensable tool for bone evaluation prior to the implant placement.

On the articulator, the incisal pin was raised 4 mm and vinyl polysiloxane (VPS) material was injected to generate an interocclusal record. This was made to serve as occlusal index during the CT scan.¹² After

the patient had the double CT-scan, the raw DICOM data were imported at a commercially available 3-D implant planning software (Nobel Guide™). The data are converted into 3-dimensional, virtual models of underlying alveolar bone and overlying prosthesis. The CT scan images alone, with acquisition slices of 0.4 mm, provide the surgeon with an accurate image of the underlying bone for diagnostic purposes but cannot be used for precise implant positioning. The virtual planning software allows interactive placement of implants with a prosthetically driven approach in relation to the existing bone, the critical anatomic structures, and the definitive prosthesis before the actual surgery.¹²⁻¹⁴

The maxilla presented with adequate bone volume to accommodate eight Branemark System dental implants (Figure 3). After

the virtual implant planning was completed, it was sent via e-mail to the Procera CAD/CAM facility in Mahwah, NJ for the fabrication of the stereolithographic surgical template. A stereolithographic surgical template was then fabricated with additive rapid prototyping. The template would be used during surgical placement of all implants and for retro-engineering of the prefabricated interim prosthesis (Teeth-In-An-Hour™).

On the day of the surgery, the surgical template was positioned and verified by interocclusal record. Three guide pins were placed for stability and uniform blanching was established. Flapless implant placement was performed under local anesthesia with strict adherence to the surgical protocol.¹⁴ The surgical procedures have been described extensively in previous publications and will not be elaborated further in this article.⁷⁻¹⁰ All

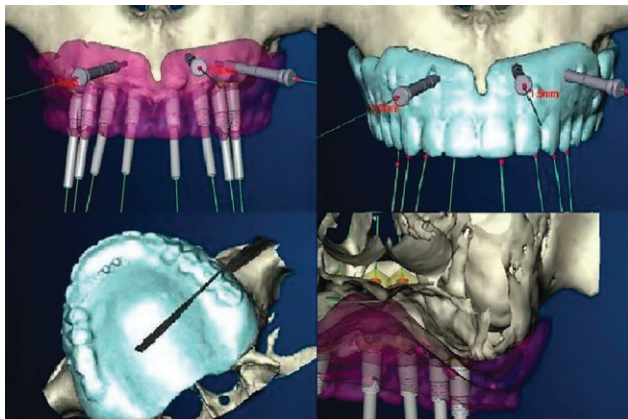


Figure 3. Virtual surgical planning with interactive software.

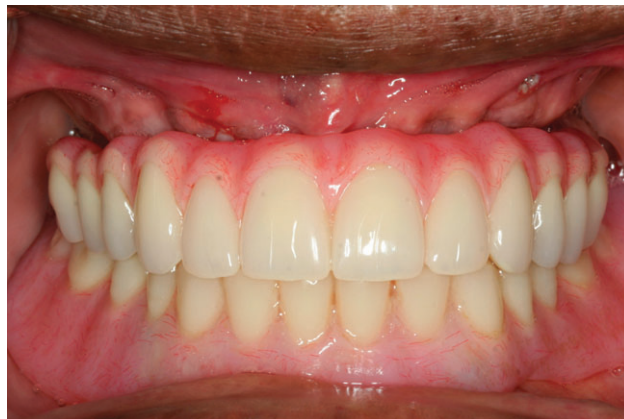

Figure 4. Prefabricated interim prosthesis in place.

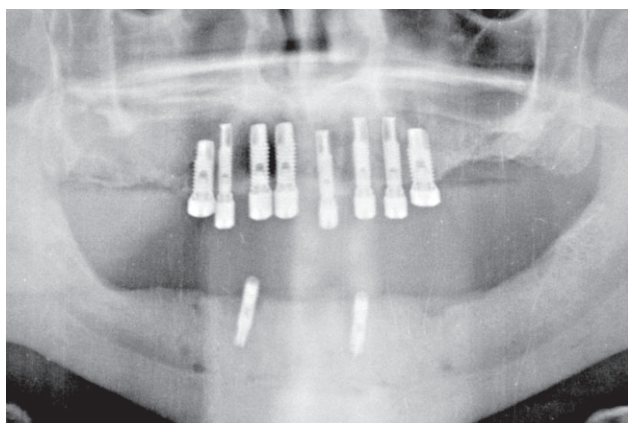


Figure 5. Postoperative panoramic radiograph.

implants achieved primary stability of 45 Ncm, thus allowing for immediate loading. Upon completion of the flapless implant placement, the implant mounts were unscrewed, the surgical template was removed and healing abutments were placed on the implants (Figure 4). Subsequently, the prefabricated interim prosthesis for immediate loading of the implants was inserted. The abutment screws

were torqued at 35 Ncm directly to the Branemark System fixtures (Figure 5). Minimal occlusal adjustments were needed to achieve cross arch centric contacts and screw access holes were filled with VPS material.

Minimizing implant micromovement, especially in early healing periods, is “conditio sine qua non” in promotion of direct bone

ingrowth to implant surface for successful osseointegration. Thus, the patient was put on a soft diet regimen for 12 weeks and was prescribed an oral irrigator for oral hygiene and analgesic medication.

One week later at the first recall, the patient expressed his satisfaction with the functional and esthetic outcome and reported no postoperative swelling and no pain. After an uneventful healing of 12 weeks, the interim prosthesis was removed and successful osseointegration of all but one of the implants was confirmed. The failed implant was removed but this loss did not have any effect on the prosthetic rehabilitation of the patient. Subsequently, impression copings were connected to the implants. The impression copings were splinted together with dental floss and visible light polymerizing acrylic resin. The acrylic

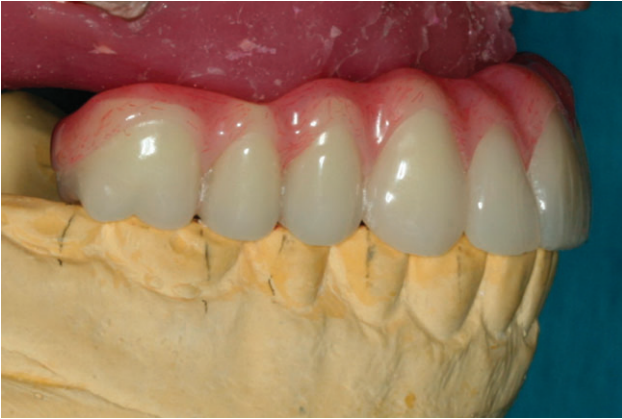

Figure 6. Maxillary working cast articulation assisted by the interim prosthesis.

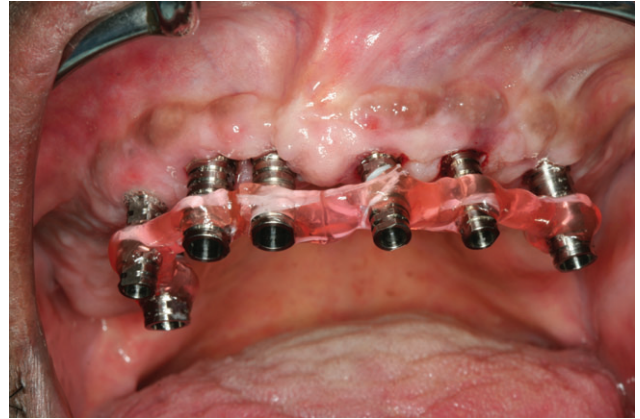


Figure 7. Intraoral verification acrylic resin jig.

resin was sectioned to allow for the polymerization shrinkage to occur and new minimal amount of acrylic resin was used to relute the copings.¹² An open tray implant level impression was made with a custom tray and polyether impression material. While the interim prosthesis was placed again in the patient's mouth, the working implant cast was poured with type IV stone in 2 increments in order to minimize the volumetric expansion.

At the next appointment, interocclusal CR records were taken in order to cross articulate the maxillary working cast with the aid of the interim prosthesis and the CR record.

Moreover, the interim prosthesis was screwed down to the working cast, and silicone buccal and lingual indices were fabricated to

aid and guide the fabrication of the definitive prosthesis within the confines of these indices (Figure 6).¹² For the fabrication of CAD/CAM zirconia prosthesis, an acrylic framework pattern needs to be designed, scanned, and milled into a zirconia framework and then veneered with feldspathic porcelain.¹⁷

Adherence to traditional prosthodontic principles in order to ensure accuracy and passivity of fit is of utmost importance, as zirconia frameworks cannot be sectioned and soldered like the metal frameworks. Thus, verification of the working cast was made by connecting non-engaging temporary abutments to the implants and splinting them with dental floss and light polymerizing acrylic resin. The whole assembly was sectioned to allow for the polymerization shrinkage and reluted with

minimal amount of resin (Figure 7). The verification acrylic jig was removed and seated on the working cast. Passive fit was obtained, thus confirming the accuracy of the working cast.¹²

The zirconia framework was designed by developing the full contour acrylic prosthesis. The acrylic prosthesis was then cut back to allow for 2 mm of veneering porcelain with respect to the confines of the silicone indices and the established tooth position and alignment (Figure 8). At this point, the decision was made to segmentalize the rehabilitation and proceed with two frameworks instead of a one-piece prosthesis. A tactile scanning machine (Nobel Forte) was used to scan the acrylic framework patterns and generate a 3-D CAD model framework. Maintenance and ease of fabrication were the reasons for this

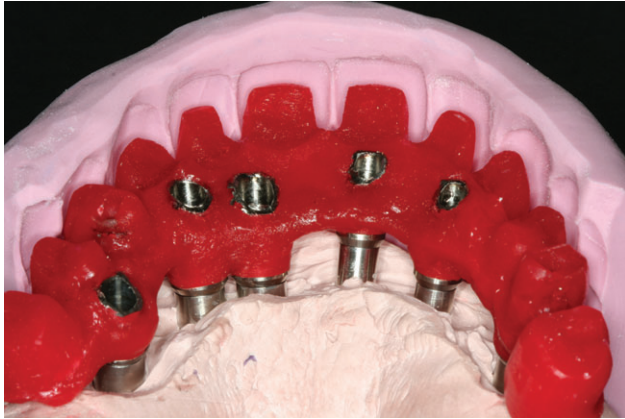


Figure 8. Acrylic framework cut back within the confines of the silicone index.

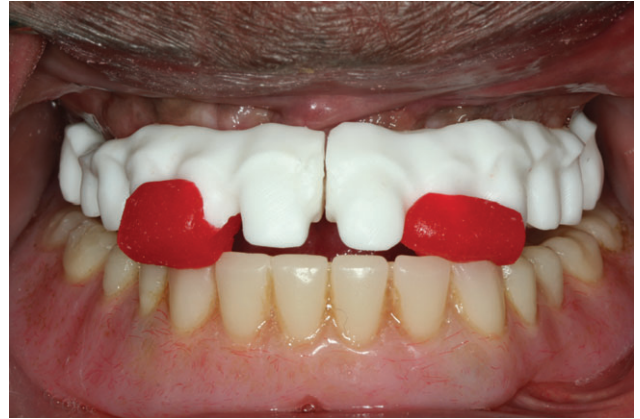

Figure 9. Zirconia frameworks and anterior deprogrammer intraorally.

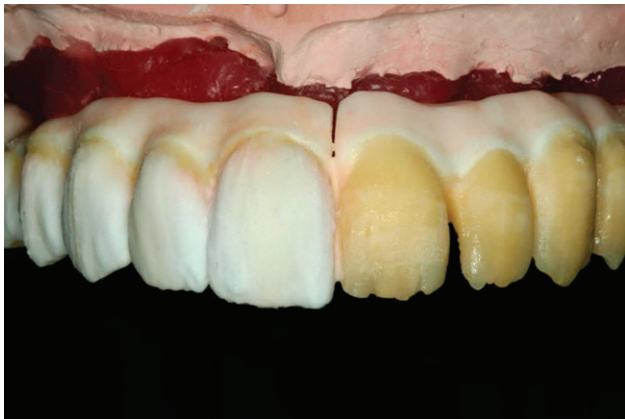

Figure 10. Porcelain build-up.

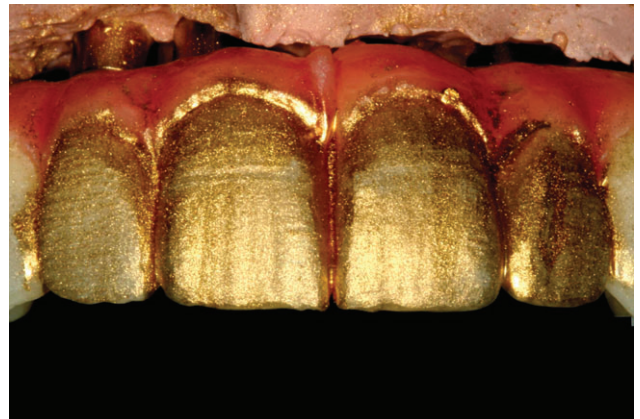


Figure 11. Porcelain surface texture contouring with gold powder.

treatment choice. The data were transferred into a CAM milling center and the zirconia frameworks were milled at the “green stage” from zirconia blocks and sintered.

The anterior deprogrammer was fabricated on the articulator to aid in the CR record and maintaining the established OVD. At the next appointment, the two

screw-retained, zirconia frameworks were tried-in for accuracy and passivity of fit. Periapical radiographs were taken and precise fit at the implant-abutment interface was verified. A new interocclusal CR record was taken with the anterior deprogrammer and VPS material to verify and transfer the jaw relation on the articulator (Figure 9). Subsequently, shade was

selected with a porcelain shade selection guide, and a pick up impression with polyether impression material was made. On the laboratory premise, the screw-retained, zirconia frameworks were veneered with feldspathic porcelain and a balanced occlusion scheme was established on the articulator for the definitive prosthesis (Figures 10–12).

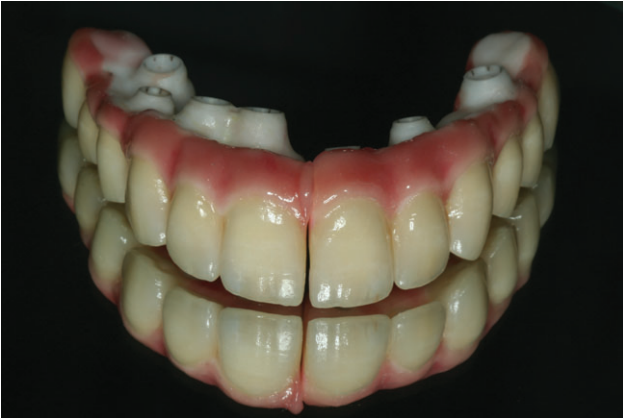

Figure 12. Definitive porcelain fused to zirconia prostheses.

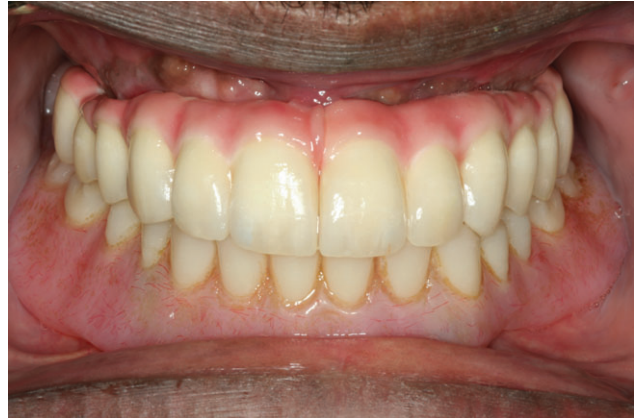

Figure 13. Intraoral evaluation of zirconia prostheses.

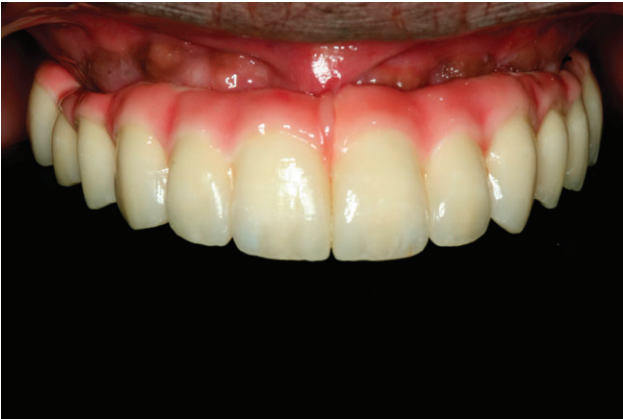

Figure 14. Post-insertion intraoral evaluation of zirconia prostheses.

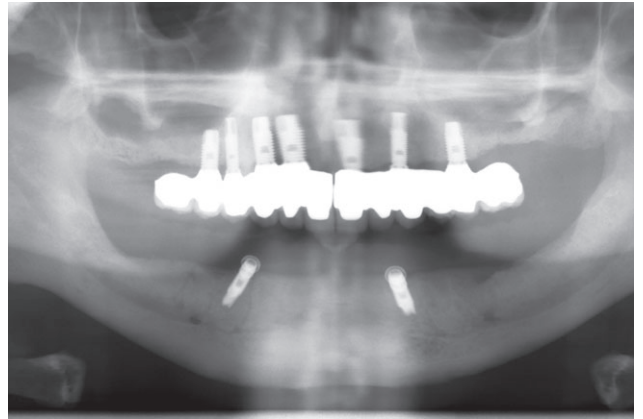

Figure 15. Panoramic radiograph 2 years after insertion of definitive zirconia prostheses.

At the delivery appointment, the definitive CAD/CAM zirconia prostheses were torqued down to the implant level at 30 Ncm. A panoramic radiograph was taken and the patient was given home oral health care instructions and advised to use the oral irrigator twice per day. The patient was highly satisfied with the final esthetic and functional outcome (Figures 13 and 14). At the

24-month post-insertion, recall appointment, the prosthesis was removed and ankylotic stability of the implants was confirmed. Panoramic and periapical radiographs verified stable marginal bone levels (Figures 15 and 16).

DISCUSSION

Surgical planning and prosthesis construction using computer technology and medical imaging for

immediate loading of implants has been made reality with CAD/CAM technology and virtual implant planning software. Advantages of computer-guided flapless implant placement include minimally invasive surgery, immediate functional loading, less postoperative sequelae, and accurate implant placement.^{7-10,12-14} As with every surgical protocol, keen attention must be given to details.

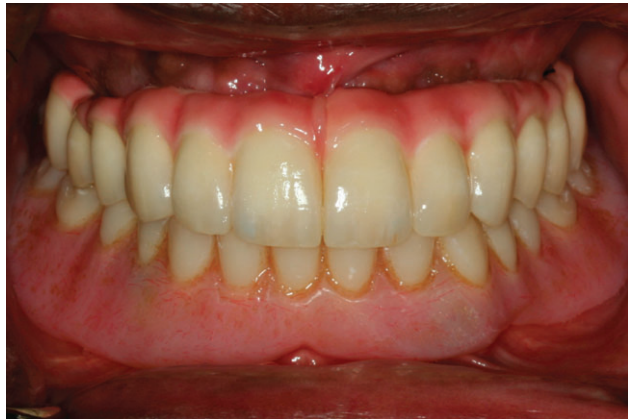

Figure 16. Post-treatment evaluation 2 years after insertion of definitive zirconia prostheses.

Good and predictable long-term outcomes of dental implants have been reported with the two-stage submerged technique.^{18–20} The last two decades, clinical studies regarding immediate loading protocols have also shown encouraging outcomes.^{1–10}

A prerequisite for immediate loading of implants is primary stability and cross arch stabilization of the fixtures. Bone quality, which generally is equivalent to bone density, represents a decisive factor as well. Roughened implant surface as well as adequate antero-posterior spread of the fixtures are also needed.²¹ All of the above mentioned factors are incumbent on the success of the surgical and restorative protocol. In addition to these factors, patient habits, namely compliance to the soft diet and bruxism have a direct effect on a successful outcome. Case selection remains

critical, and the clinician should proceed with caution when implementing immediate loading protocols in the maxilla.

In clinical studies, no statistically significant difference has been found between two-stage submerged approach and immediate loading regarding the crestal remodeling.²¹ The 2-year results for this patient demonstrated stable post-restorative bone levels. However, clinical studies have shown somewhat higher crestal bone resorption with the Teeth-In-An-Hour™ protocol according to established criteria.¹⁰ Case selection is imperative for success, since the flapless protocol is not indicated for deficient, knife-edge alveolar ridges that need reduction prior to implant installation. The crestal bone is clearly visible on cross sectional and 3D reconstructions of the CT scan. Not every patient can

be treated utilizing this technology, and knife-edge sites are avoided during the computer-guided planning of the implants.

In terms of chairside time, this flapless protocol reduces the surgical procedure and delivery of the interim restoration to 45 minutes to 1 hour, compared with 4–6 hours required for traditional immediate loading protocols.⁸

There is no difference in time line with regard to fabrication of the definitive prosthesis. In terms of cost, at present they are comparable with regard to lab expenses.

High noble alloys, base metals, and zirconia or alumina ceramics are available for fabrication of the prosthetic implant abutments. Metal substructures have been associated with reduced light transmission compared with all ceramic restorations that are more attractive because of their natural appearance. They have the advantage of the ability to section and reconnect in case of misfit. Zirconia, is a ceramic material with optimal mechanical and esthetic properties.²² Zirconia, stabilized with yttrium oxide results in high flexural strength and fracture toughness due to transformation toughening. Zirconia frameworks for fixed partial dentures on anterior and posterior teeth and on implants are currently being utilized.^{22–28} Enhanced

esthetics and core strength of the substructure are the advantages of these frameworks.²³⁻²⁶ Most all-ceramic systems have a 2-layer structure, using veneering ceramic over a strong supporting core.²⁶ This is also true for the porcelain fused to zirconia restorations, since brittle ceramics are pressed or build on top of stiff, strong cores. Zirconia cores are subject to flexure during occlusal loading but due to high flexural strength and low modulus of elasticity, they are much less susceptible to fracture than alumina cores.²⁶⁻²⁸ The bond between the veneering porcelain and the zirconia substructure is the weak link and fracture/chipping of the veneering porcelain has been noted as the most common complication.²³⁻³⁰ The functional ankylosis and reduced proprioception of osseointegrated implants correlated with higher functional forces might further exacerbate porcelain veneer delamination.

To the authors' knowledge, up to 5-year clinical follow-up data exist only for tooth-supported zirconia fixed partial dentures (FPDs).²³⁻²⁶ Preliminary reports of implant-supported zirconia crowns and FPDs have been published in the dental literature with 6-month follow-up.^{12,31,32} No long-term data are available for the longevity of implant-supported zirconia prostheses. Moreover, the effects of the fabrication procedures such as

grinding, heat treatment, sandblasting, and veneering of the zirconia substructures on the long-term stability and success of the material in implant prosthodontics has not been fully documented yet. This clinical report demonstrates a stable result with no prosthetic complications after the 2-year post-insertion follow-up. Further clinical studies pertaining to extensive implant-supported zirconia frameworks are needed.

CONCLUSION

Immediate loading of dental implants eliminates the need for interim removable prosthesis and increases patient comfort and masticatory function throughout the healing period. Computer-guided, flapless implant placement with stereolithographic templates is another option in the dentist's armamentarium. Patients can benefit from these significant advantages. Emphasizing proper patient selection, the advantages of immediate loading for patient's maxilla are shorter surgical and treatment times, a less invasive surgical technique with less swelling, less pain and the immediate use of a prefabricated fixed prosthesis. Rapid prototyping and CAD/CAM technology were utilized in the construction of the definitive prosthesis. The porcelain fused to zirconia implant prosthesis has bio-compatibility for enhanced soft tissue integration, exceptional

strength, and customized design of framework for ultimate esthetic outcomes. For this case, the patient's chief complaint was addressed, and patient and clinician satisfaction was achieved.

DISCLOSURE

The authors do not have any financial interest in the companies whose materials are included in this article.

REFERENCES

1. Schnitman PA, Wohrle PS, Rubenstein JE, et al. Ten-year results for Brånemark implants loaded with fixed prostheses at implant placement. *Int J Oral Maxillofac Implants* 1997;12:495-503.
2. Morton D, Jaffin R, Weber HP. Immediate restoration and loading of dental implants: clinical considerations and protocols. *Int J Oral Maxillofac Implants* 2004;19(Suppl):103-8.
3. Del Fabbro M, Testori T, Francetti L, et al. Systematic review of survival rates of immediately loaded dental implants. *Int J Periodontics Restorative Dent* 2006;26:249-63.
4. Nkenke E, Fenner M. Indications for immediate loading of implants and implant success. *Clin Oral Implants Res* 2006;17(Suppl 2):19-34.
5. Ostman PO, Hellman M, Sennerby L. Direct implant loading in the edentulous maxilla using a bone density-adapted surgical protocol and primary implant stability criteria for inclusion. *Clin Implant Dent Relat Res* 2005;7(Suppl 1):S60-9.
6. Cannizaro G, Leone M, Esposito M. Immediate functional loading of implants placed with flapless surgery in the edentulous maxilla: a 1-year follow-up of a single cohort study. *Int J Oral Maxillofac Implants* 2007;22:87-95.
7. Van Steenberghe D, Glauser R, Blomback U, et al. A computed tomographic scanner-derived customized surgical template and fixed prosthesis for flapless surgery and

- immediate loading of implants in fully edentulous maxillae: a prospective multicenter study. *Clin Implant Dent Relat Res* 2005;7(Suppl 1):111–20.
8. Sanna AM, Molly L, van Steenberghe D. Immediately loaded CAD-CAM manufactured fixed complete dentures using flapless implant placement procedures: a cohort study of consecutive patients. *J Prosthet Dent* 2007;97:331–9.
 9. Komiyama A, Klinge B, Hultin M. Treatment outcome of immediately loaded implants installed in edentulous jaws following computer-assisted virtual treatment planning and flapless surgery. *Clin Oral Implants Res* 2008;19:677–85.
 10. Johansson B, Friberg B, Nilson H. Digitally planned, immediately loaded dental implants with prefabricated prostheses in the reconstruction of edentulous maxillae: a 1-year prospective, multicenter study. *Clin Implant Dent Relat Res* 2009;11:194–200.
 11. Becker W, Wikesjö UM, Sennerby L, et al. Histologic evaluation of implants following flapless and flapped surgery: a study in canines. *J Periodontol* 2006;77:1717–22.
 12. Pappaspyridakos P, Lal K. Complete arch implant rehabilitation using subtractive rapid prototyping and porcelain fused to zirconia prosthesis: a clinical report. *J Prosthet Dent* 2008;100:165–72.
 13. Cheng AC, Tee-Khin N, Siew-Luen C, et al. The management of a severely resorbed edentulous maxilla using a bone graft and a CAD/CAM-guided immediately loaded definitive implant prosthesis: a clinical report. *J Prosthet Dent* 2008;99:85–90.
 14. Marchack CB. An immediately loaded CAD/CAM-guided definitive prosthesis: a clinical report. *J Prosthet Dent* 2005;93:8–12.
 15. Conrad HJ, Seong WJ, Pesun IJ. Current ceramic materials and systems with clinical recommendations: a systematic review. *J Prosthet Dent* 2007;98:389–404.
 16. Sailer I, Fehér A, Filser F, et al. Five-year clinical results of zirconia frameworks for posterior fixed partial dentures. *Int J Prosthodont* 2007;20:383–8.
 17. Chang PP, Henegbarth EA, Lang LA. Maxillary zirconia implant fixed partial dentures opposing an acrylic resin implant fixed complete denture: a two-year clinical report. *J Prosthet Dent* 2007;97:321–30.
 18. Zarb GA, Schmitt A. The longitudinal clinical effectiveness of osseointegrated dental implants: the Toronto study. Part I: surgical results. *J Prosthet Dent* 1990;63:451–7.
 19. Zarb GA, Schmitt A. The longitudinal clinical effectiveness of osseointegrated dental implants: the Toronto study. Part II: prosthetic results. *J Prosthet Dent* 1990;64:53–61.
 20. Jemt T, Johansson J. Implant treatment in the edentulous maxillae: a 15-year follow-up study on 76 consecutive patients provided with fixed prostheses. *Clin Implant Dent Relat Res* 2006;8:61–9.
 21. Mendonça G, Mendonça DB, Simões LG, et al. Nanostructured alumina-coated implant surface: effect on osteoblast-related gene expression and bone-to-implant contact in vivo. *Int J Oral Maxillofac Implants* 2009;24:205–15.
 22. Denry I, Kelly RJ. State of the art of zirconia for dental applications. *Dent Mater* 2008;24:299–307.
 23. Molin MK, Karlsson SL. Five-year clinical prospective evaluation of zirconia-based Denzir 3-unit FPDs. *Int J Prosthodont* 2008;21:223–7.
 24. Edelhoff D, Florian B, Florian W, Johnen C. HIP zirconia fixed partial dentures—clinical results after 3 years of clinical service. *Quintessence Int* 2008;39:459–71.
 25. Tinschert J, Schulze KA, Natt G, et al. Clinical behavior of zirconia-based fixed partial dentures made of DC-Zirkon: 3-year results. *Int J Prosthodont* 2008;21:217–22.
 26. White SN, Miklus VG, McLaren EA, et al. Flexural strength of a layered zirconia and porcelain dental all-ceramic system. *J Prosthet Dent* 2005;94:125–31.
 27. Tsumita J, Kokubo Y, Vult von Steyern P, Fukushima S. Effect of framework shape on the fracture strength of implant-supported all-ceramic fixed partial dentures in the molar region. *J Prosthodont* 2008;17:274–85.
 28. Aboushelib MN, de Kler M, van der Zel JM, Feilzer AJ. Effect of veneering method on the fracture and bond strength of bilayered zirconia restorations. *Int J Prosthodont* 2008;21:237–40.
 29. Aboushelib MN, Feilzer AJ, Kleverlaan CJ. Bridging the gap between clinical failure and laboratory fracture strength tests using a fractographic approach. *Dent Mater* 2009;25:383–91.
 30. Taskonak B, Yan J, Mecholsky JJ, et al. Fractographic analyses of zirconia-based fixed partial dentures. *Dent Mater* 2008;24:1077–82.
 31. Sierraalta M, Razzoog ME. A maxillary anterior partially edentulous space restored with a one-piece zirconia implant fixed partial denture: a clinical report. *J Prosthet Dent* 2009;101:353–8.
 32. Dunn DB. The use of a zirconia custom implant supported fixed partial denture prosthesis to treat implant failure in the anterior maxilla: a clinical report. *J Prosthet Dent* 2008;100:415–21.

Reprint requests: Panos Pappaspyridakos, DDS, MS, Department of Restorative Dentistry and Biomaterials Sciences, Harvard University, Harvard School of Dental Medicine, 188 Longwood Avenue, Boston, MA 02115, USA; Tel.: 617-432-1399; Fax: 617-432-0901; 646-644-7394; email: pp2229@columbia.edu

Presented at the International Federation of Esthetic Dentistry (IFED) 6th World Congress, 2–5 August 2009, Las Vegas, NV, USA: 3rd Prize at the Poster Presentation Competition.

This article is accompanied by commentary, “Immediate Loading of the Maxilla with Prefabricated Interim Prosthesis Using Interactive Planning Software, and CAD/CAM Rehabilitation with Definitive Zirconia Prosthesis: 2-Year Clinical Follow-up,” Stephen Rimer, DDS, DOI 10.1111/j.1708-8240.2010.00344.x